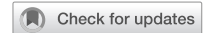

EDITORIAL



Abusive head trauma and the eye in infants and children - clinical guideline update by the royal college of ophthalmologists and the royal college of paediatrics and child health: executive summary

© Crown 2024

Eye (2024) 38:1783–1786; <https://doi.org/10.1038/s41433-024-02977-7>

INTRODUCTION

Abusive head trauma (AHT) in infants and children is a form of child maltreatment. Those infants and children suspected of being subjected to abusive head injury are often referred by paediatricians to the on-call ophthalmology team for examination of signs of overt external ocular injury or occult vitreoretinal trauma. On occasion a child may first present to an ophthalmologist with signs of ocular trauma where the history may not be consistent with the extent or type of trauma, or the signs may indicate a fabricated or induced illness. A pre-mobile infant for example may present to the ophthalmologist with subconjunctival haemorrhages which may be a sentinel sign of abusive injury.

The ophthalmic manifestations of AHT play an important and significant role in the decision making process of further investigations of abusive injury. However, a wide differential diagnosis should be considered in the presence of such eye signs because underlying medical disorders can present with signs which overlap those seen in AHT. Legal proceedings for safeguarding a child suspected of abusive injury often require an ophthalmologist to provide a detailed report and interpretation of the ophthalmic findings. It is hence incumbent on every ophthalmologist to be familiar with the clinical presentations and clinical signs of child maltreatment, how best to document these findings and to be aware of child protection investigations and procedures.

This paper is a summary of the updated evidence-based guidelines on Abusive Head Trauma and the Eye published by the Royal College of Ophthalmologists and the Royal College of Paediatrics and Child Health. Additional literature on new-born retinal haemorrhages, non-vitreoretinal injury and fabricated or induced illness have been included. The document has been developed to support an ophthalmologist called upon to evaluate a child suspected of child abuse. It provides an evidence-based resource of:

1. The ophthalmic findings, differential diagnosis and confounding conditions that may have features suggestive of AHT.
2. How to evaluate a child suspected of AHT, the methods of documentation and imaging.
3. Interpretation of signs and further investigations that may be useful.

4. How to find local procedures to follow when dealing with child protection.
5. How to provide a factual report of clinical findings with a balanced interpretation of findings supported by current literature.

METHODS

A guideline working party (GWP) developed nine main clinical questions which aligned to a number of sub questions from the previous guideline with additional new questions for the purpose of a literature search. Text words from the previous guideline with additional text words for the new questions considered, were used by an information specialist for the literature search. The following data bases were searched; CINAHL (*Cumulative Index to Nursing and Allied Health Literature*), Cochrane Library, EMBASE, MEDLINE ALL; Scopus, Web of Science Core Collection: Citation Indexes, Science Citation Index Expanded (SCI-EXPANDED), Social Sciences Citation Index (SSCI), Conference Proceedings Citation Index- Science (CPCIS), Conference Proceedings Citation Index- Social Science & Humanities (CPCI-SSH).

Results

A total of 20,338 titles and abstracts were identified for the period between 2011 and 2021 with additional hand search for new papers added until the time of full paper review. There were 159 papers called for full reviews and after exclusion of conference proceedings, expert opinion, editorials and non systematic reviews, 115 were selected for critical appraisal. Using a standardised critical appraisal form and two appraisers critically evaluating each paper, 70 papers were included for this update. Additional material from NICE guidance allowed the GWP to develop good practice points and guidance for the ophthalmologist.

RESULTS

This is a summary of the synopsis of studies reviewed for each question in developing the guideline. If no new data was reviewed a summary from the previous guideline is included. The summary review for each clinical question is presented under four subject headings; (a) Aetiological factors and experimental models in AHT, (b) Clinical features, investigations and pathology in AHT, (c) Differential diagnosis and confounding conditions that have overlapping features with AHT and (d) Guidance for the Ophthalmologist.

Received: 16 January 2024 Revised: 24 January 2024 Accepted: 30 January 2024
Published online: 5 March 2024

Aetiological factors and experimental models

What forces are needed to produce retinal haemorrhages and other signs of intraocular trauma in infants without direct ocular injury? The forces involved in producing retinal haemorrhages in abusive head trauma are not known. Information on the forces involved is extrapolated from observational, experimental studies using computational and animal models. Studies using finite element models of simulated infants report on the suggested location in the retina, the amount of force and the type of rotational forces involved in AHT. The limitations of computer models in extrapolating the forces involved in producing retinal injury in infants subjected to abusive injury is acknowledged. While the actual forces involved in human subjects is not known, this update suggests that the forces are considerable, associated with rotation injury and located at the vitreoretinal interface along blood vessels and the macula.

Is additional impact (in addition to shaking injury) necessary for the production of very severe ocular injury? In addition to a shaking injury, impact may contribute to the severity of retinal damage but is not mandatory for its production. In experimental research there remain uncertainties regarding the likely mechanical events leading to particular patterns of injury. Severe retinal haemorrhages occur in some crush and head impact injuries but may be seen without any associated evidence of direct impact to the head.

Can normal handling (such as vigorous play) cause retinal and intracranial haemorrhages? There is no published evidence of retinal haemorrhages occurring as a result of normal handling or vigorous play with infants or children.

What are the postulated mechanisms of retinal haemorrhages in abusive and non-abusive head trauma? Evidence is indirect, and the mechanisms may well be mixed in most cases. There are some pointers towards the likely predominant mechanism in certain circumstances: external forces; confessed shaking injury, with/without impact is very often associated with numerous, bilateral RHs; shaking may indicate potential vitreous traction with external forces, and additional internal forces. In accidental impact trauma RHs are only associated with severe, high velocity injuries. Head crush injury (abrupt severe elevation of intravascular pressure) can produce severe RHs.

Does hypoxia give rise to the clinical picture of AHT? Hypoxia resulting from apnoea or associated with choking or respiratory arrest during vomiting has not been shown to cause the clinical picture of AHT. Retinal hypoperfusion with ischaemia as a result of non-accidental injury may lead to the later development of preretinal fibrovascular proliferation and tractional retinal detachment.

What are the current computer and biomechanical models of AHT? A perfect biofidelic model of an infant does not exist and hence forces that are required to produce ocular injury calculated on current models will be imprecise. Data from recent computational models using finite element analysis suggest that shear forces are exerted maximally at the posterior retina. Computer modelling has been used to examine the effects of shaking and falls on the eye. These are helpful in understanding the mechanisms producing retinal bleeding.

Are there any suitable animal models of AHT? There are no satisfactory primate or non-primate models reported that replicate retinal injury seen in children with abusive head trauma.

Clinical features, investigations and pathology

Are retinal haemorrhages in child abuse more common in infants than in older children? Retinal injury in AHT is commonly

reported in children under three years of age. The highest prevalence is seen in infancy (less than 12 months) although case studies of older children have been reported.

What is the usual site and extent of retinal haemorrhages (RH) in AHT? A systematic review on the diagnostic accuracy of ocular signs has reported a sensitivity of 75% and a specificity of 94% of intraocular haemorrhage in AHT. Bilateral retinal haemorrhages are commonly reported. RHs are often too numerous to count and extend from posterior pole to ora serrata. RHs may be unilateral and asymmetrical but they are more often reported as severe, multi-layered, and bilateral.

Are any ocular fundus findings pathognomonic of child abuse? There are no fundus findings pathognomonic of child abuse though multi-layered retinal haemorrhages that are bilateral involving the posterior pole and periphery, retinal folds and retinoschisis may be highly suggestive of it. The ocular fundus findings need to be evaluated with other systemic findings present.

Are unilateral retinal haemorrhages compatible with child abuse? While retinal haemorrhages are more commonly bilateral in cases of abusive head trauma, cases with unilateral haemorrhages do occur. They also occur in accidental head trauma, and in other pathologies. When they occur in association with unilateral intracranial haemorrhage, they are often but not exclusively ipsilateral.

Can intraocular haemorrhage increase after injury? The area of retinal haemorrhage can increase in about one third of cases, but the number of haemorrhages do not increase. This has implications for timing of injury based on area of retinal haemorrhage/s.

Is it possible to determine from an examination of the retina, the time at which an injury occurred or whether there have been haemorrhages at more than one time? Data on the age of bruising of the skin by its change in colour is controversial. Current scientific evidence concludes that is not possible to age bruises from inspection and a parallel can be drawn with retinal haemorrhages. The majority of intraretinal haemorrhages will clear within two weeks but there is a range reported of up to 58 days for isolated intraretinal haemorrhage to resolve. Large pre-retinal haemorrhages take longer to clear. The presence of multiple intraretinal haemorrhages with preretinal haemorrhage suggests recent trauma within a few days of the retinal examination, but an isolated preretinal haemorrhage with few or no intraretinal haemorrhages may suggest a longer interval from the trauma.

Are there any retinal findings without intracranial findings or encephalopathy? RHs are relatively rare in the absence of encephalopathy or intracranial bleeding in AHT. CT imaging is relatively insensitive in picking up small subdural haemorrhages and very thin film subdural bleeding. MRI is thus used as definitive method to increase diagnostic yield. However, it appears that in some severely injured children, early CT and MR imaging may indicate an absence of intracranial haemorrhage but reveal extensive cerebral oedema. Marked cerebral oedema may prevent intracranial blood accumulation and may in fact be a marker of more severe head injury.

Are retinal haemorrhages secondary to intracranial bleeding? Current evidence demonstrates that intraocular bleeding secondary to intracranial haemorrhage from intracranial pathology or accidental trauma is rare in young children. Retinal findings however may closely resemble those seen in AHT. Cases

where intraocular and intracranial haemorrhage are seen together include those with clear evidence of a ruptured aneurysm, severe accidental head injury, epidural haemorrhage and neurosurgical intervention. The severity of the ocular findings being directly related to the severity of the intracranial event with an acute, sharp rise in intracranial pressure playing a role in the mechanism of retinal haemorrhages.

Is intracranial damage always accompanied by retinal haemorrhages in AHT? No. There is clear evidence that retinal haemorrhage is found in approximately two-thirds of intracranial injury caused by abusive head trauma.

What is the optic nerve and orbital pathology seen in AHT and non AHT? Optic nerve sheath haemorrhages are common in AHT, however, they may also be seen in cases of accidental head injury. The only study which specifically examined orbital tissues in detail found that bleeding into orbital fat and especially the extraocular muscles and posterior orbit may be of significance in distinguishing AHT from accidental injury, but more work is required to confirm this. Scleral haemorrhage at the junction between the optic nerve and sclera is common in AHT, and is seen in association with optic nerve sheath haemorrhage (ONSH) and RH, but the number of studies documenting this finding is small. β -APP (β - amyloid precursor protein) immunohistochemistry is a useful adjunct to routine histopathological staining to allow detection of axonal injury in the optic nerve. In a small case series, optic nerve axonal injury was demonstrated in cases diagnosed as shaking or shaking-impact head trauma. Further work is required to determine the specificity of these findings for abusive head trauma and mechanism of injury. Head crush injury can be associated with bilateral ONSHs, as described in the previous review. ONSHs has been described in an unusual case of infantile myocardial infarction with an anomalous coronary artery, occurring in the context of DIC (disseminated intravascular coagulation) and anaemia which was difficult to distinguish from abusive head trauma.

What is the vitreous/retinal pathology in AHT and non AHT? Condensed vitreous attached to the apices of perimacular folds has been demonstrated histologically in 5 cases of abusive head trauma, supportive of vitreoretinal traction as a pathogenic mechanism for macular retinoschisis and perimacular fold formation.

Differential diagnosis and confounding conditions

Can accidental injury cause retinal haemorrhages? RHs are rare in accidental injury. Though the majority of reports suggest that these RHs are mainly mild in severity and predominantly unilateral, few in number either pre or intraretinal and located to the posterior pole. A pattern of bilateral extensive multi-layered RHs extending from the posterior pole to the periphery, associated with retinoschisis and retinal folds has been the subject of a few case reports and autopsy series with predominantly severe crush head injury.

What other conditions of childhood may have retinal haemorrhages? Retinal haemorrhages occur in a number of systemic and ocular conditions, ocular trauma, birth trauma, accidental head injury, intracranial disease, bleeding disorders, systemic and ocular infections.

For how long can birth-related retinal haemorrhages persist? Recent papers confirm that RHs are common in neonates affecting up to 40% of infants born by SVD. Most resolve rapidly within 2 weeks though dense foveal intraretinal RHs may persist

for months. They are more prevalent after assisted births, particularly those involving vacuum extraction, but are less common after elective Caesarean sections.

Can bleeding diathesis or blood dyscrasia cause retinal haemorrhages similar to those seen in child abuse? RHs have been reported in Vitamin K deficiency, DIC, thrombocytopenia, platelet function disorders, factor I, factor V, factor VIII, factor IX and factor XI deficiency. RHs in leukaemia can be difficult to distinguish from those in AHT, but the abnormal white cell count and other features would help to distinguish leukaemia from AHT. Extensive RHs have been described in Von Willebrand's disease and vitreous haemorrhages in protein C deficiency. If bleeding disorders co-exist with AHT a haematological opinion should be sought, bearing in mind that AHT can also cause secondary coagulation abnormalities.

Can seizures alone cause retinal haemorrhages as seen in cases of child abuse? RHs are rarely caused by seizures alone. If RHs are found in a child with convulsions, this finding should prompt a search for another cause.

Can cardio-pulmonary resuscitation cause retinal haemorrhages? CPR is very unlikely to cause RHs, even if carried out by unskilled individuals. A caveat could be added to exclude very premature children with acute ROP on the basis of a case report. CPR alone continues to be unlikely in isolation to cause RHs, and when associated the pattern of RHs reported are mild. The additional presence of DIC and hypoxic brain injury may be a contributing factor.

Can prolonged vomiting, or gagging cause retinal haemorrhages? RHs appear to be very rare (if at all they occur) as a result of Valsalva manoeuvre in young children. The current update did not identify any new reports to support RH occurring as a result of vomiting or gagging.

Is an apparent life-threatening event (ALTE) or brief resolved unexplained event (BRUE) associated with retinal haemorrhages? The literature does not support BRUE (formerly known as ALTE) as a causative mechanism of retinal findings.

Are vaccinations associated with retinal haemorrhages? The literature does not support vaccinations or immunisations as a cause of RHs.

Do high cervical injuries from any other source give rise to retinal haemorrhages? Evidence exists of a higher prevalence of radiological injury to the high cervical spine in AHT compared to accidental injury and non-traumatic cases where the spine was imaged but the retinal findings were not reported.

Can short distance falls cause retinal haemorrhages? Short distance falls are unlikely to cause retinal haemorrhages if the injury is not severe. A recent study reported no RH in children who had falls less than 1 m.

Do retinal haemorrhages similar to AHT occur with raised intracranial pressure? RHs are rare in raised ICP in nontraumatic causes. RHs are not seen without papilloedema. When present they are small, do not extend beyond the peripapillary area and are associated with papilloedema.

What are the ocular findings in crush injury? Extensive, multi-layered, bilateral retinal bleeding, or bilateral asymmetric bleeding, retinoschisis and perimacular folds can occur in isolated cases of accidental crush head trauma. Few to widespread RHs have been reported in crush injuries to the infant head.

Which methods are useful in imaging the retina in AHT? Various contact and non-contact retinal cameras are useful in documentation of retinal findings. Use of non-contact ultra-widefield scanning laser ophthalmoscope (Optos P200MA) provides high quality imaging but its utility remains limited at present. The opportunity to detect evidence of RHs with ocular ultrasound and MR scanning early in the evaluation of AHT may be considered as part of the child protection protocol. OCT imaging in AHT helps in elucidating the vitreoretinal relationship in AHT, and in the long term may provide structural and functional correlates.

Which features or characteristics of non-vitreoretinal eye injury are present in child maltreatment, neglect and fabricated or induced illness? (a). Subconjunctival haemorrhages: There was no one type of injury that is highly specific for abusive trauma, but the fact that all described cases in one series had subconjunctival haemorrhage suggests that this could be regarded as a 'sentinel injury' that should prompt further consideration of abuse. (b). Fabricated or induced illness: Evidence from a single case of keratoconjunctivitis caused by the instillation of caustic substance in the eye has been reported.

Guidance for the ophthalmologist

Procedures for the ophthalmologist and documentation when a safeguarding concern arises. If ophthalmologists have concern about child maltreatment this section guides the ophthalmologist on documentation of findings and making a referral to the child protection team. It provides further guidance on how to find local procedures to follow for child protection. It also includes clinical features that would alert an ophthalmologist to the possibility of child maltreatment. It provides guidance on eye examination after a sudden infant death.

Standards of ophthalmology assessment. This section provides the ophthalmologist with guidance on how to complete an ophthalmology assessment and the details to be systematically documented. A template has been suggested for recording of eye findings.

Timing of ophthalmology assessment. Good practice supports an ophthalmology assessment by the on-call ophthalmology team within 48 hours of an initial paediatric referral.


CONCLUSIONS

This paper should be used as a companion guide to the full guideline published on the Royal College of Ophthalmologists and Royal College of Paediatrics and Child health websites. It provides the ophthalmologist with a useful summary of current literature in AHT and the eye. The differential diagnosis and

confounding conditions that have overlapping features with abusive injury support the ophthalmologist and other clinicians involved in child protection to rule out or consider alternative diagnoses. Guidance for the ophthalmologist provides good practice points on what to do when abusive injury is suspected, when to examine a child, how to examine and how to record findings in a child suspected of abusive injury.

DATA AVAILABILITY

The data used to develop the guideline is sourced from publications in medical literature. The reference list with the full guideline is available on the Royal College of Ophthalmologists website in the guideline section.

Patrick Watts¹✉, Gillian Adams², Susmito Biswas³, Paul Davis¹, Paul Leach¹, I. Christopher Lloyd⁴, Jo McPartland⁵ and Alan Mulvihill⁶ 

¹University Hospital of Wales Cardiff, Cardiff, UK. ²Moorfields Eye Hospital London, London, UK. ³Manchester Royal Eye Hospital Manchester, Manchester, UK. ⁴Great Ormond Street Hospital London, London, UK. ⁵Alder Hey Children's Hospital Liverpool, Liverpool, UK. ⁶Royal Hospital for Children and Young People Edinburgh, Edinburgh, UK. ✉email: Patrick.Watts@wales.nhs.uk

ACKNOWLEDGEMENTS

Consultant Ophthalmologists (Anne-Marie Hinds: Moorfields Eye Hospital, London, Jeremy Butcher: Wirral University Teaching Hospital, Wirral, Saurabh Jain: Royal Free Hospital, London, Sunila Jain: Lancashire Teaching Hospitals, Preston); Specialist Ophthalmology trainees (Adonis El Saloukh: ST6: Wales deanery, Alexander Stubbing-Moore: ST4: Wales deanery, Arpitha Periera: ST5: Wales deanery, Colm McAlinden: ST6: Wales deanery, Frederick Burgess: ST7: North East deanery, James Potts: ST6: Wales deanery); Barny Foot (Facilitator, Scientific Committee, Royal College of Ophthalmologists), Mala Mann (information specialist Cardiff University).

AUTHOR CONTRIBUTIONS

The first draft of this paper was written by PW. All authors edited and commented on several versions of this manuscript.

FUNDING

The Royal College of Ophthalmologists funded the literature search. There was no funding for the time and work carried out by all the authors.

COMPETING INTERESTS

All authors declare that they have no competing interests. GA, JM, SB, CL, AM and PW undertake or have previously undertaken medico legal work in child maltreatment cases.